

Indication of penetrating Keratoplasty in Hospital Universiti Sains Malaysia

Abdulrahman A Bawazir

عبد الرحمن أحمد باوزير

*Department of Ophthalmology,
School of Medical Sciences, Universiti Sains Malaysia,
Health Campus, 16150 Kubang Kerian, Kelantan – Malaysia.
Faculty of Medicine, Hadhramot University for Science and Technology –
Yemen.*

Mohtar Ibrahim

مختار إبراهيم

Wan Hazabbah WH

وان هزابه

*Department of Ophthalmology,
School of Medical Sciences, Universiti Sains Malaysia,
Health Campus, 16150 Kubang Kerian, Kelantan – Malaysia.*



جامعة الأندلس
العلوم والتقنية

Alandalus University For Science & Technology

(AUST)

Indication of penetrating Keratoplasty in Hospital Universiti Sains Malaysia

ABSTRACT

Our objective in this study is to describe the indication of penetrating keratoplasty operations in Hospital Universiti Sains Malaysia (HUSM).

A retrospective study on patients admitted for perform PK operation in the Department of Ophthalmology at the University of Seines Malaysia Hospital; Kota Baharu- Kelantan (HUSM) from June 2005 until June 2010. . A review of the patients' medical records for demographic data, history, clinical examinations, related laboratory investigations and PK indications, diagnosis of glaucoma, aphakia, with notification of optical and refractive parameters pre and post- operative Data collected from the process of the follow-up were also considered up to April 2010. Cases with non-corneal button transplantation had excluded.

Penetrating keratoplasty was performed in twenty three eyes of nineteen patients. Twelve (63.2%) were males and 7 (36.8%) females. The mean age was of 51.7 years (± 15.6) and the range of 16-72 years. Nineteen (82.6%) eyes had primary PK and 4 (17.4%) eyes have secondary penetrating keratoplasty. The indication of PK in 7 eyes (30.4%) was infected keratitis (fungal, pseudomonas and viral), other 5 eyes (21.7%) were diagnosed with traumatic corneal injury (chemical/ non chemical). In 4 (17.4%) eyes had post Aphakic/Pseudophakic bullous keratopathy and the last three eyes (13%) with keratoconus.

The pre-operative best corrected visual acuity of twenty eyes (87%) ranged from perception of light to counting fingers, while those of the remaining three eyes (13%) were found with 6/36. Post PK on the last follow up period the best corrected visual acuity was ranged between 6/60 and 6/7.5 in 5 eyes, and in 15 (65.2%) eyes between perception of light and 1/60 and three eyes with no light perception.

The major indication of PK in this study was the infected Keratitis with perforated corneal ulcer followed by traumatic corneal injuries. Eyes with post-operative PK and with uncontrolled IOP graft failure and visual impairment were frequently seen. The larger size study is recommended to conduct to be able to generalize the results.

Key words: Penetrating keratoplasty, indication, Hospital Universiti Sains Malaysia, Kota Baharu, Malaysia.

INTRODUCTION

Corneal blindness is considered globally as one of the crucial factor for vision impairment [1]. Bilateral corneal blindness found as a major cause of visual handicap, as a consequence of a high incidence of corneal infection and ulceration. However, penetrating keratoplasty (PK), as a surgical procedure since more than 100-years [2], is considered as one of the world's most widely practiced human organ and tissue transplantation method for treating blindness [3]. In addition, it provides improvement of the ophthalmologic status in both- the doctor's and patient's opinion where 95% of good prognosis were found with the current techniques, such as in keratoconus. On the other hand, poor prognosis could be found in such cases with sever dry eyes, chemical burns, pemphigoid, where the success rate is much lower and approaches zero percent [4].

However in ophthalmology, PK is relatively an expensive procedure due to high price of donor cornea, long hospitalization, repeat outpatient visit, and time-and cost –consuming visual rehabilitation which usually applicable in expert corneal centers with high safety and storage standards of transplants [5].

The Malaysian National Eye Survey 1996, revealed that the corneal diseases were responsible for 3.4% of blindness and 2.5% of low vision, which considered as notable causes of visual impairment [6]. Since 1970, national ophthalmology centers that performing PK were established gradually up to 46 in 2005 [7]. This procedure was also implemented recently in our university hospital, as a tertiary level health facility for the state but not yet assessed.

Objectives :

The objective of this study is to describe the indication of penetrating keratoplasty operations in Hospital Universiti Sains Malaysia (HUSM).

Methods :

A retrospective study was performed on patients admitted for PK operations in the Department of Ophthalmology at the University of Seines Malaysia Hospital; Kota Baharu- Kelantan,(HUSM) during the period from June 2005 until June 2010. A review of the patients' medical records for demographic data, history, clinical examinations, related laboratory investigations and PK indications, diagnosis of glaucoma, aphakia, with notification of pre and post-operative optical and refractive parameters [uncorrected visual acuity (UCVA), best corrected visual acuity (BCVA), graft clarity, anterior chamber depth, inflammatory reaction, intraocular pressure, and fundus evaluation if possible]. Follow-up period

range from one month to 56 months (mean \pm SD=18.4 \pm 15.1 months). The study excluded those patients with non-corneal button transplantation.

The indications for KP were divided into 9 large categories; modified from those used by elsewhere [8-11]. These includes Keratitis with Fungal Ulcerative conditions¹; Trauma²; Chemical injury and Scarring³; Keratoconus⁴; Aphakic and Pseudophakic bullous keratopathy⁵; Pseudophakic and Glaucoma valve implantation with bullous keratopathy⁶; Congenital Fuchs' dystrophy⁷; Regraft⁸; and Non-Fuchs' dystrophy⁹.

Results:

Penetrating keratopathy was performed in twenty three eyes of nineteen patients. Twelve (63.2%) were males and 7 (36.8%) females. The mean age was of 51.7 years (\pm 15.6) and the range of 16-72 years. Nineteen (82.6%) eyes were with primary PK. Two of them were keratoconus of the same patient. Four eyes were exposed to previous re-graft, three of them from the previous 19 eyes and one patient with rejected graft from another hospital, as seen in table 1. Fifteen patients (78.9%) were from the same state (Kota Baharu- Kelantan), 10 of them referred from Kelantan state hospitals, private clinics, and five directly followed the ophthalmology clinic. The remaining four patients were referred from Johor and Terengganu states hospital.

The indication of primary PK in 7 eyes (30.4%) was infected keratitis (fungal, pseudomonas and viral), other 5 eyes (21.7%) were diagnosed with traumatic corneal injury (chemical/ non chemical). In 4 (17.4%) eyes post Aphakic/Pseudophakic bullous keratopathy was the indication, one of them with glaucoma valve implantation and the last three eyes (13%) were with keratoconus, two of them for the same patient. In addition other PK indications

were detected in congenital scleral- corneal degeneration, Fuchs' dystrophy, Regraft and non- Fuchs' dystrophy one for each (4.35%)

Pre-operative secondary closed angle glaucoma was diagnosed in five eyes (21.7%) and other five (21.7%) eyes developed post PK secondary glaucoma.

Figure1. show the BCVA readings pre and post PK. The pre-operative BCVA of twenty eyes (87%) ranged from perception of light to counting fingers while those of the remaining three (13%) eyes were found with 6/36. Post PK operations the best corrected visual acuity ranged between light perception and 1/60 in 15 (65.2%) eyes and it was no light perception three (13%) eyes.

Table1. Patient's characteristic on pre and post PK

Patient No.	Age (yrs) /sex	Eye Oper.	Corneal Diagnosis	Glaucoma Diagnosis	Aphakic Status	No. of Regraft Surgeries	IOP (mmHG) (preop/ final)	Visual Acuity preop, final	Follow-up Months /days
1	16/M	RE	Keris. +PFCU	None	Phakic	0	5/18	HM, 6/24	11/23
2	65/M	RE	PBK	2nd ACG	PCIOL	0	12/18	HM, NLP	19/16
3	42/M	RE	Trum.+ PBK	Traumatic	PCIOL	0	21/20	CF, 1/60	34/19
4	48/M	LE	Pseudom. Ker./PCU	2nd OAG	Phakic	0	45/24	LP, NLP	11/7
5	60/F	LE	Fuch's Syndr.	None	PCIOL	0	10/25	CF, CF	39/18
6	36/F	BE	Keratoc.	None	Phakic BE	0	14/15 12/26#	CF, 5/60 CF, 1/60#	22/4
7	61/M	RE	PBK	2nd ACG , TE+Valave Implantatio	PCIOL	0	14/33	CF, HM	21/28

Indication of penetrating Keratoplasty in Hospital Universiti Sains Malaysia

Abdulrahman A Bawazir , Mohtar Ibrahim , Wan Hazabbah WH

				n					
8	45/M	LE	Keratoc.+Tumr Scar.	None	Aphakic	0	15/18	CF, 6/24	10/23
9	51/F	RE	Chem. Trum.Scar	None	Phakic	0	15/18	CF, 1/60	13/8
10	55/M	LE	Trum.Keris. +PFCU	None	Phakic	0	22/19	PL, HM	8/26
11	45/M	RE	Chem. Trum. +BK	2nd ACG + TE	Phakic	1	28/24 20/ 29*	HM, PL PL/ CF*	56/25
12	58/F	LE	Keris. +PVCU	None	Phakic	0	18/22	HM, CF	0/8
13	70/F	LE	Trum. + PCU	None	Phakic	1	14/10 10/ 27*	6/36, 1/60 CF, HM*	30/21
14	53/F	RE	Keris. +PCU	None	Phakic	0	14/10	HM, 6/7,5	40/0
15	20/M	LE	Cong.Sclero- corneal deg.	None	Phakic	0	13/10	HM, HM	1/27
16	29/F	LE	Failed graft/Chem. Trum.	2nd ACG	Phakic	1	27/33	6/36, NLP	14/20
17	67/M	LE	Non Fuch's Keratop.	None	Phakic	0	10/15	HM, 6/45	8/10
18	68/M	RE	Keris. +PFCU	None	Phakic	1	12/16 16/19*	PL, PL PL, PL*	10/29
19	72/M	LE	Keris. +PCU	None	Phakic	0	22/32	HM, CF	1/16

Keris: Keratitis, P FCU: Perforated Fungal corneal ulcer, HM: Hand movement, PBK: Pseudophakia Bullous Keratopathy, Trum: Trauma, Pseudom. Ker.: Pseudomonus keratitis, PCU: Perforated

Corneal ulcer. Keratoc: Keratoconus, TE: Trabeculectomy, ACG: Angle close glaucoma, Chem.: Chemical, BK: Bullous Keratopathy, PVCU: Perforated Viral corneal Ulcer, Cong. : Congenital, PL: Perception of light. CF: Counting Fingers. NLP: No light perception, #: result of the other PK eye, *: result after regraft.

PL: Perception of light. CF: Counting Fingers. NLP: No light perception

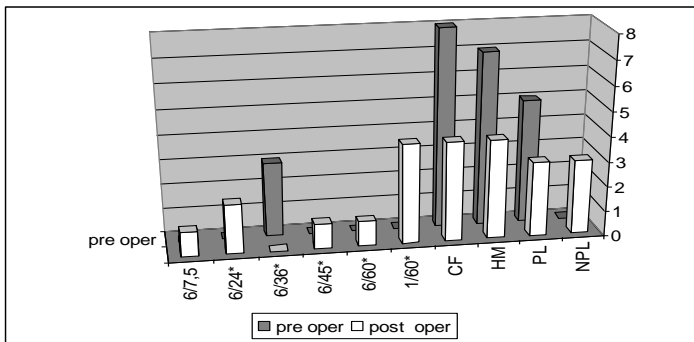


Figure 1 stated best visual acuity pre and post PK

Discussion:

Penetrating keratoplasty is an effective treatment for selective corneal disorders (12). This type of intervention, however, had highly successful improvement of vision and quality of life for those patients who underwent PK after being with corneal blindness (5, 13). Among the 23 eyes who had been operated 19 (82.6%) of them were considered as primary PK. However, three (15.8%) of them were re-grafted due to rejection of the first graft; sever button infection or secondary glaucoma. One eye had been re-grafted for the first time due to failure of previous PK done elsewhere.

Several papers reported that Pseudophakic bullous keratopathy was the first indication of PK (8, 14, 15)._In our case, we found that

infected Keratitis with perforated corneal ulcer (30.4%) was the major indication of PK, followed by traumatic corneal injuries and post Aphakic/Pseudophakic bullous keratopathy comes as the 3rd cause of PK. These findings were inconsistent with what was found by Dorrepaal or Dandona (16, 17).

In those cases with post PK secondary glaucoma the uncontrolled IOP leads consequently to graft failure and visual impairment. Five eyes (21.7%) were developed post PK secondary glaucoma which is in accordance with other studies of secondary glaucoma followed PK with an incidence of 9-35% (18). Sinha et al, showed that post-PK glaucoma were ranged between 26.6% in cases and up to 50% in controls (2), which is higher than what we found in our study. On the other hand Karimian et al, state that secondary glaucoma was not a significant cause of graft failure in PK (19).

Fifteen (65%) eyes post PK their BCVA was between perceptions of light and 1/60, five eyes range between 5/60, and 6/7.5, and three eyes with no light perception. Thirteen eyes BCVA <3/60 which not concise with other study done elsewhere (2, 20).

CONCLUSION:

The study concluded that penetrating keratoplasty is an effective treatment for selective corneal disorders with highly successful improvement of vision and quality of life for those patients with corneal blindness. Grafting of the eye has to be performed carefully from being contaminated and infected. The major indication of PK in this study was the infected Keratitis with perforated corneal ulcer followed by traumatic corneal injuries. However in cases with post PK secondary glaucoma and with uncontrolled IOP, graft failure and visual impairment were frequently seen.

Despite the good results obtained from this study, findings should be interpreted fairly because of the limited number of the sample size which also considered as the main limitation of this study. Therefore, larger size study is recommended to be conducted in order to be able to generalize the results.

ACKNOWLEDGEMENT:

The authors wish to express their grateful thanks to workers of the department of the registration University of Seines Malaysia Hospital; Kota Baharu- Kelantan,(HUSM) for their helpfulness. And to Amin A Bawazir –PhD-, Faculty of Medicine-Aden University, for his thoughtful comments on this essay.

References

1. Foster A and R. S., The impact of vision 2020 on global blindness. *Eye*, 2005. 19: p. 1133-35.
2. Sinha, R., et al., Outcome of penetrating keratoplasty in patients with bilateral corneal blindness. *Eye (Lond)*, 2005. 19(4): p. 451-4.
3. Hong Jia-xu, et al., Pediatric penetrating keratoplasty in Shanghai: a retrospective multiple center study from 2003 to 2007. *Chin Med J*, 2008. 121 ((19)): p. 1911-14. Clayman, H.M., *Atlas of Contemporary Ophthalmic Surgery*. 1990.
4. Hirneiss, C., et al., Cost utility for penetrating keratoplasty in patients with poor binocular vision. *Ophthalmology*, 2006. 113(12): p. 2176-80.
5. Zainal M, et al., Prevalance of blindness and low vision in Malaysian population: results from the national Eye Survey 1996. *Br J Ophthalmol* 2002. 86: p. 951-956.
6. Hooi L S and Y. ML., National Transparent Registry. *Medical Journal Malaysia*, 2008. 63: p.9-12.
7. Haamann, P., O.M. Jensen, and P. Schmidt, Changing indications for penetrating keratoplasty. *Acta Ophthalmol (Copenh)*, 1994. 72(4): p. 443-6.
8. Mamalis, N., et al., Changing trends in the indications for penetrating keratoplasty. *Arch Ophthalmol*, 1992. 110(10): p. 1409-11.
9. Al-Yousuf, N., et al., Penetrating keratoplasty: indications over a 10 year period. *Br J Ophthalmol*, 2004. 88(8): p. 998-1001.
10. Siganos, C.S., et al., Changing indications for penetrating keratoplasty in Greece, 1982-2006: a multicenter study. *Cornea*. 29(4): p. 372-4.

11. Beckingsale, P., et al., Penetrating keratoplasty: outcomes from a corneal unit compared to national data. *Br J Ophthalmol*, 2006. 90(6): p. 728-31.
12. Keenan, T.D., et al., Trends in corneal graft surgery in the UK. *Br J Ophthalmol*.
13. Brady, S.E., et al., Clinical indications for and procedures associated with penetrating keratoplasty, 1983-1988. *Am J Ophthalmol*, 1989. 108(2): p. 118-22.
14. Ghosheh, F.R., et al., Trends in penetrating keratoplasty in the United States 1980-2005. *Int Ophthalmol*, 2008. 28(3): p. 147-53.
15. Dandona, L., et al., Indications for penetrating keratoplasty in India. *Indian J Ophthalmol*, 1997. 45(3): p. 163-8.
16. Dorrepaal, S.J., K.Y. Cao, and A.R. Slomovic, Indications for penetrating keratoplasty in a tertiary referral centre in Canada, 1996-2004. *Can J Ophthalmol*, 2007. 42(2): p. 244-50. 8
17. Dada, T., et al., Post-penetrating keratoplasty glaucoma. *Indian J Ophthalmol*, 2008. 56(4): p. 269-77.
18. Farid Karimian, A.-R.B.-R., Sepehr Feizi, Mohammed Zare, Mohammed-Reza Jafarinasab. Mohammed-Ali Javadi, Ali Mirdehghan, Bahram Einollahi , Outcomes of penetrating keratoplasty for macular corneal dystrophy. *J Ophthalmic Vis Res*, 2009. 4(1): p. 14-18.
19. M Vanathi, et al., Indications and outcome of repeat penetrating keratoplasty in India. *BMC Ophthalmology* 2005. 5: p. 5-26.

دواعي إجراء عمليات زراعة القرنية بين مرضى عمليات العيون في مستشفى العلوم الجامعي بماليزيا - كوتابارو - ولاية كلينتان - ماليزيا

أجريت هذه الدراسة الوصفية التراجعية بين المرضى الذين أجريت لهم عمليات جراحية في قسم العيون بمستشفى العلوم الجامعي بماليزيا - بمدينة كوتابارو ، ولاية كلينتان في الفترة من يونيو ٢٠٠٥م حتى فبراير ٢٠١٠م. تم تصميم استمارة خاصة بجمع المعلومات ذات العلاقة بالمرضى المرقدين التي أجريت لهم عمليات زراعة القرنية الأولية أو الثانوية بالقسم والتي تضمنت معلومات ديموغرافية عن المريض و التاريخ المرضي ونتائج الفحص الإكلينيكي والمخبري والتشخيص المؤدي لهذه العملية ، الأمراض العينية المصاحبة لتعتم القرنية كالإصابة بضغط العين عمليات إزالة العدسة ومعدلات البصر قبل وبعد العملية. المعلومات المثبتة أثناء العملية والمتابعة الدورية للمريض حتى إبريل ٢٠١٠م. مع إستثناء الحالات التي لم يتم لها زراعة قرنية أنسية.

أوضحت النتائج المستخلصة للدراسة أنه بلغت عدد الأعين التي أجريت لها عملية زراعة القرنية ثلاثاً وعشرين عيناً لتسعة عشر مريضاً. منهم اثنا عشر ذكراً (63.2%) ، وسبع من الإناث (36.8%) ، المتوسط العمري لهم ٥١.٧ (±15.6) عاماً ، ما بين ١٦-٧٢ عاماً . لقد أجريت عملية زراعة القرنية لتسعة عشر (82.6%) عيناً لأول مرة ، وأعيد زراعة القرنية للمرة الثانية لأربعة (17.4%) أعين. إن دواعي إجراء عملية زراعة القرنية الأولية -حسب التسلسل العددي - تمثلت في سبع عيون مصابة بالتهابات تقرحية للقرنية ، وخمس عيون إصابات كيميائية وغير كيميائية ، و أربع عيون نتيجة لتعتم القرنية الثنائي بعد عمليات الساد الأبيض ، أما العيون الثلاث الأخيرة فكانت نتاج للقرنية المخروطية.

من خلال دراسة أفضل معدلات البصر قبل عملية زراعة القرنية تبين أن عشرين (87%) عيناً يتراوح بصرها بين تحديد مصدر الإضاءة إلى عد الأصابع ، بينما ثلاثة (13%) عيون حدة البصر لديها ٦/٣٦. أما بعد عملية زراعة القرنية وفي آخر زيارة متابعة للحالات اتضح أن خمسة عيون أفضل معدلات البصر لديها يتراوح من ٦/٦٠ إلى ٦/٧,٥ ، وخمسة

عشر عيناً أفضل معدلات البصر لديها يتراوح بين تحديد مصدر الإضاءة إلى ١/٦٠ ، بينما ثلاثة عيون الأخيرة فاقدة البصر وغير قادرة على تحديد مصدر الإضاءة. استخلصت الدراسة أن أرفع النسب لدواعي إجراء عمليات زراعة القرنية في هذا المستشفى هي الالتهابات القرنية ، تليها إصابات القرنية النافذة ، وبينت الدراسة أن هناك بعض العيون التي خضعت لعملية زراعة القرنية أصيبت بمضاعفات عدم السيطرة على الضغط العيني المصاحب بفشل العملية بتعمق القرنية الثانوي؛ لذلك توصي الدراسة بتوسيع الجانب العددي لحالات عمليات زراعة القرنية حتى يتم تعميم النتائج المترتبة على ذلك.

الكلمات المفتاحية: زراعة القرنية ، الدواعي الطبية ، مستشفى العلوم الجامعي بماليزيا ، كوتابارو ، ماليزيا.